

Presentation Title: **Rare presentation of *Plasmodium*** ***Falciparum* with pancytopenia in a** **16-year-old adolescent**

Author(s): S. Rodriguez, MD; S. Chen Lin, MD; C. Oberto, MD; C. Marino, MD

Institution(s): NYC + Health Hospitals / Lincoln

PI Name:

PI Facility:

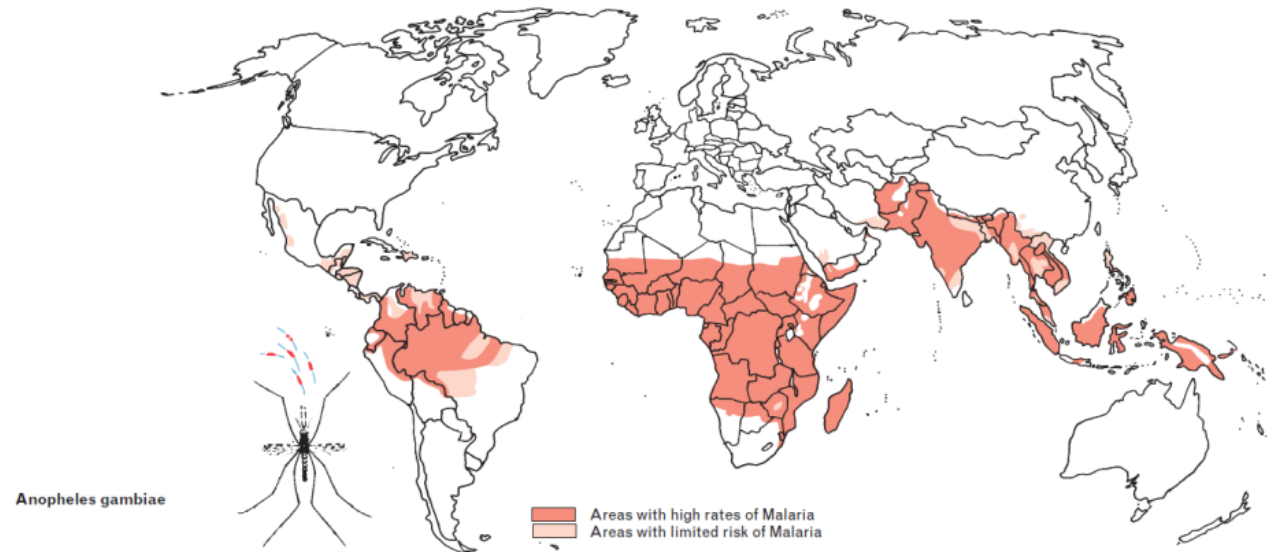


Financial Disclosure

- *We have no actual or potential conflict of interest in relation to this program*

Introduction

Malaria is a parasitic infection caused by Plasmodium, transmitted by female Anopheles mosquitoes, which is not endemic in the United States (US). If untreated, it can lead to severe complications such as acute renal failure, liver dysfunction, cerebral malaria and potentially death. Symptoms can be vague, including fever, chills, flu-like symptoms, headaches and vomiting. Rarely, it can cause pancytopenia. Given the non-specific presentation, diagnosing malaria can propose a diagnostic challenge at times



Case description

A 16 year-old female with history of treated latent tuberculosis and esotropia of the right eye, was brought in by mother to the Emergency Department (ED) with complaints of abdominal pain, nausea and vomiting for 1 week, both patient and her mother denied recent history of travel outside of the United States (US). Vitals signs in the ED were within normal limits. Physical examination was pertinent for dry mucous membranes, and bilateral, lower quadrant abdominal tenderness on palpation. Abdomen was non distended and bowel sounds were present. The initial blood work up was remarkable for leukopenia, anemia, with no reticulocytosis, thrombocytopenia, increased inflammatory markers (CRP, ESR and LDH), mild hyponatremia, and hypokalemia. Patient was admitted due to dehydration complicated by electrolyte derangements and inability to tolerate oral intake.

Cont.

During admission acute pancreatitis, surgical abdomen, and autoimmune etiology were ruled out. Patient remained hemodynamically stable, symptoms improved, electrolyte disturbances resolved and the patient was discharged home with a follow up appointment. Patient was seen in the primary care clinic 4 days after discharge and a CBC showed persistent leukopenia, and a reflex blood smear was positive for malaria parasites. Malaria rapid screening test was positive and the patient was readmitted for antimalarial treatment and close monitoring. On admission, the patient was febrile (101.1F) with other vital signs within normal limits. Upon further questioning, the patient admitted to recent travel to Africa 2 months prior to initial presentation. Treatment was started and blood parasites remained <1.0%. Patient was subsequently discharged in stable condition.

Discussion

In 2022, there were about 249 million malaria cases worldwide, resulting in 608,000 deaths, mainly affecting children in sub-Saharan Africa. The United States reports around 2,000 cases annually, mostly among travelers and immigrants returning from malaria-endemic regions.

Malaria often leads to various blood-related complications, including anemia, thrombocytopenia, leucopenia, neutropenia, leukocytosis, atypical leukocytosis, and splenomegaly. These hematological changes depend on factors such as malaria prevalence, existing hemoglobin disorders, demographic factors and immunity levels.

Cont.

Less common complications include pancytopenia and hemophagocytic lymphohistiocytosis (HLH), particularly with *Plasmodium falciparum*. The exact mechanism behind these findings remains unclear. One of the proposed causes of these complications is an excessive immune response, involving a cytokine storm triggered by natural killer cells and cytotoxic T-cells. This response releases cytokines like IL-1 IL-2, IL-6, TNF- α , INF- γ , and M-CSF, leading to macrophage activation, phagocytosis of blood cells, suppressed bone marrow function, and disrupted clotting, which collectively contribute to pancytopenia.

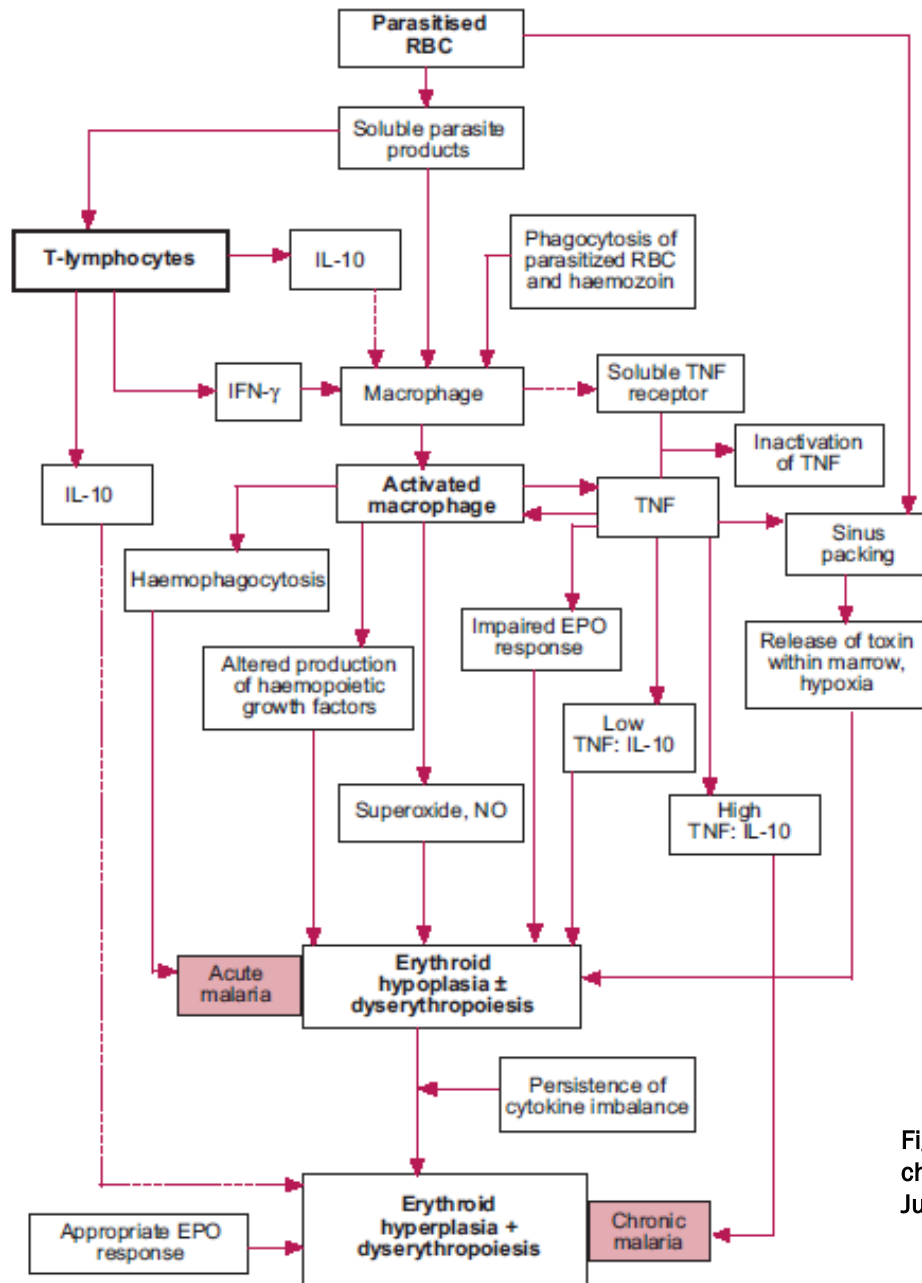


Fig. 1, Reference: Wickramasinghe SN, Abdalla SH. Blood and bone marrow changes in malaria. Baillieres Best Pract Res Clin Haematol. 2000 Jun;13(2):277-99. doi: 10.1053/beha.1999.0072. PMID: 10942626.

Conclusion

This case highlights the importance of considering malaria in the differential diagnosis of pancytopenia, especially in patients with a history of travel to endemic regions. Pancytopenia in malaria, although rare, can be attributed to several mechanisms, including direct parasitic effects, bone marrow suppression, hypersplenism, hemophagocytic syndrome, and immune-mediated destruction. Malaria-induced pancytopenia is a rare but serious condition that demands careful consideration and prompt, aggressive treatment for a positive outcome.

Reference

1. Awoke N, Arota A (2019) Profiles of hematological parameters in Plasmodium falciparum and Plasmodium vivax malaria patients attending Tercha General Hospital, Dawuro Zone, South Ethiopia. Infect Drug Resist.
2. Anabire NG, Aryee PA, Helegbe GK (2018) Hematological abnormalities in patients with malaria and typhoid in Tamale Metropolis of Ghana. BMC Res Notes.
3. Wickramasinghe SN, Abdalla SH. Blood and bone marrow changes in malaria. Baillieres Best Pract Res Clin Haematol. 2000 Jun;13(2):277-99. doi: 10.1053/beha.1999.0072. PMID: 10942626.
4. World malaria report 2023. Geneva: World Health Organization; 2023. Licence: CC BY-NC-SA 3.0 IGO

Questions?